

# Systematic review of the use of platelet-rich plasma in aesthetic dermatology

Michael S Leo, BS,<sup>1</sup> Alur S Kumar, MD,<sup>2</sup> Raj Kirit, DNB, DDVL,<sup>3</sup> Rajyalaxmi Konathan, MD,<sup>4</sup> & Raja K Sivamani, MD, MS, CAT<sup>5</sup>

<sup>1</sup>School of Medicine and Public Health, University of Wisconsin-Madison, Madison, WI, USA

<sup>2</sup>Department of Dermatology, Owaisi Hospital and Research Centre, Hyderabad, India

<sup>3</sup>Sainath Skin Clinic, Himayathnagar, Hyderabad, India

<sup>4</sup>Department of Dermatology, Venereology, and Leprosy, Central Hospital South Central Railway, Hyderabad, India

<sup>5</sup>Department of Dermatology, University of California, Davis, Sacramento, CA, USA

## Summary

Platelet-rich plasma (PRP) is a highly concentrated autologous solution of plasma prepared from a patient's own blood. PRP contains platelets that are purported to release numerous growth factors that may be valuable in numerous dermatologic applications. Here, we review systematically the clinical cosmetic applications of PRP including: androgenetic alopecia, scar revision, acne scars, skin rejuvenation, dermal augmentation, and striae distensae to understand the potential and best practices for PRP use. A systematic search was conducted on three databases: Pubmed, Embase, and Web of Science. Publications were included if they were in English, investigated the clinical applications of PRP in aesthetic dermatology and reported clinical results either as case reports or clinical studies. There were a total of 22 manuscripts that fulfilled these criteria. Four evaluated hair-related applications, eight evaluated the treatment of scars and postprocedure recovery, eight evaluated skin rejuvenation and dermal augmentation, and two evaluated treatment of striae distensae. PRP is a relatively new treatment modality with studies suggesting its utility in aesthetic dermatology. The combination of PRP with other therapies is particularly interesting. Future studies should include controls, including incorporation of split-face comparisons, to reduce intersubject variability.

**Keywords:** platelet-rich plasma, aesthetic, cosmetic, dermatology, review, facial rejuvenation

## Introduction

Platelet-rich plasma (PRP) is an autologous solution of plasma containing 4–7 times the baseline concentration of human platelets.<sup>1</sup> It is prepared from centrifuging a patient's own blood<sup>1</sup> and has been used for

various dermatological conditions including wound healing, anti-inflammatory, and cosmetic uses.<sup>2–4</sup> PRP contains various growth factors contained in alpha granules and dense granules. Alpha granules contain seven fundamental growth factors: the platelet derived growth factors (PDGF $\alpha\alpha$ , PDGF $\beta\beta$ , and PDGF $\beta\alpha$ ), transforming growth factor beta (TGF $\beta$ 1 and 2), epithelial growth factor (EGF), and vascular endothelial growth factor (VEGF).<sup>5,6</sup> These growth factors modulate cell proliferation, differentiation, angiogenesis, and chemotaxis. The dense granules contain bioactive factors

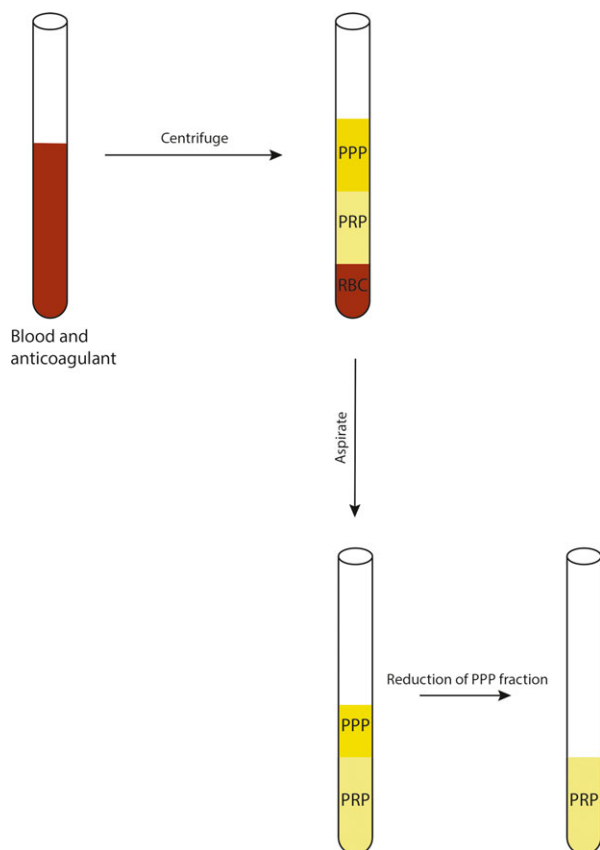
Correspondence: Raja Sivamani, Assistant Professor of Clinical Dermatology, Department of Dermatology, University of California, Davis, 3301 C Street, Suite 1400, Sacramento, CA 95816, USA. E-mail: rksivamani@ucdavis.edu

Accepted for publication June 27, 2015

including serotonin, histamine, dopamine, calcium, and adenosine.<sup>7</sup> These bioactive factors can increase membrane permeability and modulate inflammation.

There are theoretically four subsets of platelet-rich plasma<sup>8</sup>: pure PRP, leukocyte and PRP (L-PRP), platelet-rich fibrin matrix (PRFM), and leukocyte- and platelet-rich fibrin matrix. The majority of studies have been conducted with pure PRP and L-PRP. Pure PRP is the most commonly used form consisting of a buffy coat with a large number of platelets with little leukocytes being collected. This review focuses on the use of pure PRP (Fig. 1) as it is the form that has been primarily studied in aesthetic dermatology.

Platelet activators such as thrombin or calcium chloride are used to activate PRP.<sup>9</sup> Adding CaCl<sub>2</sub> and centrifuging results forms a loose fibrin matrix called PRFM, which entraps growth factors and releases them



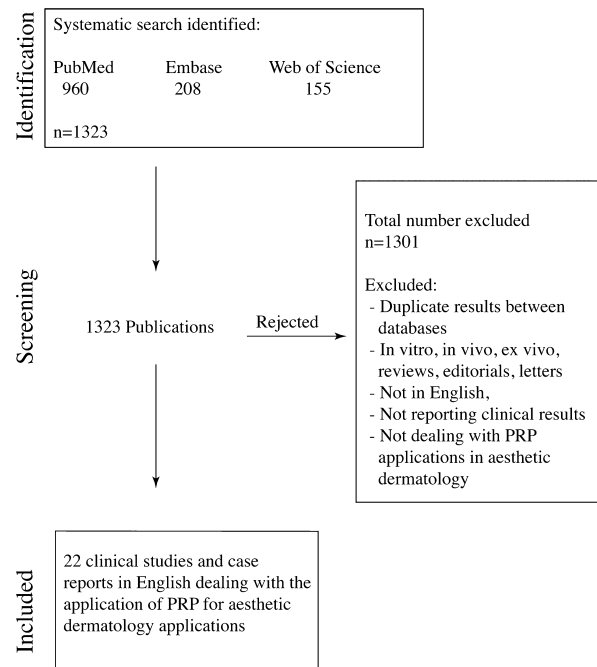
**Figure 1** Platelet-rich plasma preparation. Blood is drawn and an anticoagulant is added. The mixture is centrifuged and separated into three layers: platelet poor plasma (PPP), platelet-rich plasma (PRP), and red blood cells (RBCs). To make PRP, the RBCs are discarded and centrifuged again. The majority of the PPP is discarded, and the end product consists mostly of PRP with a small amount of PPP. Thrombin or calcium chloride is added as platelet activators.

over 7 days. It is used more often in procedures such as fat grafting or soft tissue augmentation due to the slower secretion over a longer time period. The final subset consists of leukocytes and PRFM (L-PRFM) and can be processed from blood without adding any anti-coagulants. Furthermore, L-PRFM does not require any activators (Table 1). The methods to generate the various subsets of PRP have been reviewed in detail.<sup>9</sup>

## Materials and methods

A systematic search of PubMed, Embase, and Web of Science databases was performed and included studies through 23 April 2014. The research criteria were as follows: (1) manuscripts written in English; (2) studies involving the application of PRP for the aesthetic dermatology treatment of hair, skin, cutaneous, cosmetic, nail, alopecia; (3) reporting clinical results as case reports or clinical studies (Fig. 2).

All articles containing the words “platelet-rich plasma” combined with the words “dermatol” or “hair” or “skin” or “cutaneous” or “cosmetic” or “nail” or “alopecia” or “wound” or “burns” or “scar” or “keloid” or “hypertrophic” were identified. The search term was (English [Language] AND (Dermatol\* OR hair OR skin OR cutaneous OR Cosmetic\* OR nail OR alopecia OR wound OR burns OR scar OR keloid OR hypertrophic) AND



**Figure 2** Schematic for systematic search. A total of 1323 articles were reviewed, and 22 publications met the inclusion criteria for the use of platelet-rich plasma (PRP).

**Table 1** Type of platelet-rich plasma/fibrin

Type of platelet-rich plasma	Preparation methods	Final components
Pure platelet-rich plasma	Anticoagulated whole blood is centrifuged. Then, PPP and a portion of the buffy coat are collected. Then, high force centrifugation is performed and PPP is discarded	Fibrin-rich plasma with concentrated platelets. Leukocyte poor
Leukocyte- and platelet-rich plasma Platelet-rich fibrin	Anticoagulated whole blood is centrifuged. Then, PPP and all of the buffy coats are collected Anticoagulated whole blood is centrifuged. Then, PPP and the entire buffy coat are collected with a separator gel for use during clotting and centrifugation process. The buffy coat and PPP are stimulated to clot in the presence of CaCl <sub>2</sub> . Then, high force centrifugation is performed and the resultant clot is then collected	Fibrin-rich plasma with concentrated platelets, leukocytes, and red blood cells Fibrin polymerized clot that is rich in platelets and variably rich in leukocytes.
Leukocyte- and platelet rich fibrin	Venous blood is collected in glass tube and centrifuged without anticoagulant. The resulting clot is collected	Fibrin polymerized clot that is rich in platelets and leukocytes

PPP, platelet poor plasma.

(("platelet-rich plasma" AND (MeSH) OR "platelet-rich plasma")). This search produced 1323 papers in total from the three databases: 960 from PubMed, 208 from Embase, and 155 from Web of Science. Reviews, *in vitro* and animal studies were excluded. Manuscripts involving wound healing were excluded as there was a recent systematic review on PRP and wound healing.<sup>10</sup> Additional relevant manuscripts were abstracted from bibliographies. Manuscripts that related to noncosmetic interventions were excluded. The results were reviewed independently by two of the authors (MSL and RKS), and any discrepancies were discussed among all of the authors for inclusion vs. exclusion. At the end of this selection, 22 manuscripts were considered eligible for inclusion as studies or clinical case reports: four evaluated hair-related applications, eight evaluated the treatment of scars and postprocedure recovery, eight evaluated skin rejuvenation and dermal augmentation, and two evaluated striae distensae (Table 2).

#### Hair thinning and alopecia

Platelet-rich plasma has been studied in hair growth and in treating androgenetic alopecia. Injections of PRP and PRP/dalteparin and protamine microparticles (PRP-DP) were administered at 2 to 3 week intervals for 12 weeks to patients with thin hair, as measured by the diameter of hair shafts.<sup>11</sup> Each person served as their own control with a similar site on the contralateral side injected with saline. Results revealed that both the PRP and the PRP-DP groups had similar

amounts of increased mean number of hairs compared with the control group. The PRP-DP significantly increased hair diameter in comparison with the PRP treatment group. Furthermore, both the PRP and the PRP-DP had similar increases in proliferation of collagen fibers and fibroblasts and increased angiogenesis around hair follicles and thickened epithelium in comparison with the saline injection sites.<sup>11</sup> Four weekly PRP injections to one side of a patient's scalp with male patterned frontal recession and hair thinning resulted in a growth rate of 0.109 mm/day compared to 0.062 mm/day on the other half of the head injected with saline control.<sup>12</sup> Injections of PRP enriched in CD34+ cell treatment were studied for androgenetic alopecia.<sup>13</sup> Male and female patients with hair loss were treated with CD34+ cells containing PRP, while another group was treated with interfollicular placental extract injections. Both treatment groups showed a mean improvement in number of hairs, hair thickness, and mean two-point scores (a measure that incorporated both hair thickness and density) by 3 and 6 months. PRP treatment with CD34+ cells showed a significant improvement in hair thickness and overall clinical presentation compared to the placental extract solution.<sup>13</sup> However, it was not clear how the PRP and the placental extract solution differed.

A separate study treated patients with hair loss and androgenic alopecia with five PRP injections over a course of 2 months, although no control or placebo group was tested.<sup>14</sup> In total, 90.5% of patients had a mean positive pull test of 8 hairs before treatment and

**Table 2** Studies with platelet-rich plasma

Cosmetic Indication	Mode of platelet-rich plasma used	Control group	Split side study	Outcome	Subjects	Reference
Hair-related applications						
Androgenetic alopecia and thin hair	Injections of PRP or PRP/dalteparin and protamine microparticles	Yes: Saline	Yes	Both treatments increased mean number of hairs and thickened epithelium	26	11
Androgenetic alopecia	PRP injections onto half of scalp	Yes: Saline	Yes	Increased mean growth rate of hair	1	12
Androgenetic alopecia	PRP containing CD34+ cells	Yes: Placental extract	No	Improved clinical presentation, hair thickness, and number of hairs	26	13
Androgenetic alopecia	PRP injections	No	No	Improved pull test results and improved hair volume and quality	42	14
Scar-related applications						
Scar revision	Injection of adipose tissue combined with PRP	No	No	Prolonged fat graft survival 1 year post surgery	1	15
Traumatic scar revision	Fat graft and L-PRP or fat graft and L-PRP combined with nonablative surgery	No	No	Significant improvements as demonstrated through the Manchester scar scale	60	16
Scar revision	PRP injections 7–10 days prior to fat grafts or PRP injections combined with fat grafts	Yes: Group 1: lipografting alone Group 2: lipografting + PRP pretreatment Group 3: Split face study of lipografting vs. lipografting +PRP	Yes: in group 3	Methods for assessment not clearly described and outcomes were not reported in quantitative fashion with statistics. All treatment groups showed qualitative aesthetic improvements with poorly described measures.	28	17
Acne scars	Topical PRP gel after erbium fractional laser therapy	No	No	90.9% of patients demonstrated clinical improvements of 50% or more by the third treatment	22	18
Acne scars	L-PRP injections after ablative CO <sub>2</sub> fractional resurfacing	Yes: Saline	Yes	Improved clinical appearance of scars and reduced duration of both erythema and edema	14	19
Acne scars	Either L-PRP injection or topical L-PRP after fractional CO <sub>2</sub> laser therapy	Yes: Saline/injected PRP vs. topical PRP	Yes	Both topical and intradermal PRP presented significant improvements in clinical appearance of acne scars	30	20
Postprocedure recovery applications						
Rhytides	Topical L-PRP application after fractional CO <sub>2</sub> laser therapy	Yes: Saline	Yes	PRP treatment resulted in decreased levels of erythema and melanin and treatment led to improved TEWL recovery	25	21
Rhytides	PRP injection after deep-plane rhytidectomy. It was not clear whether PRP included buffy coat or not.	Yes: Splitface PRP/untreated	Yes	Reduced ecchymosis and edema in patients following surgery	8	22
Facial rejuvenation and dermal augmentation applications						
Face and neck rejuvenation	PRP injections	No	No	Improved naso-labial folds, horizontal neck bands, skin micro-relief, snap test, skin homogeneity and texture, skin tonicity, and periocular wrinkles	23	26

**Table 2** (continued)

Cosmetic Indication	Mode of platelet-rich plasma used	Control group	Split side study	Outcome	Subjects	Reference
Dermal augmentation of inner arms	Injected PRP	No	No	Stimulated angiogenesis, neocollagenesis, and adipogenesis	4	29
Derm augmentation of melolabial folds	PRP injections	No	No	Improved melolabial folds as evaluated by the Wrinkle Assessment Scale	5	30
Infraorbital dark circles	PRP injection	No	No	Improved color homogeneity of infraorbital dark circles	10	27
Infraorbital wrinkles and skin tone	PRP injection	Yes: split-face PRP/saline and split-face PRP/platelet poor plasma	Yes	PRP significantly improved both wrinkles and skin tone in patients. PRP analysis was pooled rather than assessed individually in each split-face treatment group.	20	28
Facial skin rejuvenation	Topical PRP with fractional laser therapy	Yes – Fractional laser therapy only	No	Increased elasticity while reducing erythema. Increased number of fibroblasts	22	4
Dermal augmentation of facial skin	PRP injection combined with fat grafting. It was not clear whether PRP included buffy coat or not.	No	No	2-year follow-up revealed positive preservation of cosmetic results	1	31
Dermal augmentation of gluteal skin	PRP combined with fat grafts	No	No	Results showed promising patient satisfaction	24	32
Striae distensae applications						
Striae distensae	PRP injection combined with intradermal radiofrequency	No	No	All patients showed improvement from the procedure with certain patients responding better as assessed through evaluations of photographs	19	34
Striae distensae	Ultrasound-enhanced topical PRP therapy after treatment with plasma fractional radiofrequency	No	No	Treatment decreased width of the widest striae from 0.75 to 0.27 mm. Furthermore, 72.2% of patients were very or extremely satisfied with treatment	18	35

PRP, platelet-rich plasma; L-PRP, leukocyte- and platelet-rich plasma.

PRP treatment resulted in negative pull tests for all patients with a mean of 3 hairs. Clinical and macroscopic evaluations revealed improved hair volume and quality. However, PRP had reduced efficacy in patients with marked alopecia type VI-VII according to the Norwood classification in men.<sup>14</sup>

### Scar revision

#### *Traumatic scars*

Scar tissue after cutaneous injuries leads to both aesthetic and functional complaints for patients. Several studies have evaluated the potential of PRP to treat scar tissue. Fat grafting is a cosmetic procedure used to restore soft tissue defects. Simultaneous injection of adipocytes with PRP has been shown to produce posi-

tive aesthetic results for scars.<sup>15</sup> Combining PRP with fat grafting prolonged fat survival for 1 year.

Another study evaluated the use of L-PRP in conjunction with a nonablative fractionated laser. Patients with traumatic scars were divided into three treatment groups: fat grafts mixed with L-PRP, nonablative laser treatment, and a combination of the two.<sup>16</sup> The influence of L-PRP was not evaluated separately and was studied in conjunction with fat grafting. Physicians evaluated the scars according to the Manchester Scar Scale (MSS) criteria using a four-point scale to measure scar color, contour, texture, and distortion. The fat graft-L-PRP treatment resulted in a two-point improvement, and the nonablative laser group showed a three-point improvement and the combination group demonstrated a four-point improvement in the MSS.<sup>16</sup> All of the results

were statistically significant improvements. Another study aimed at examining the benefits of PRP in scar treatment divided patients into three groups: lipografting without PRP (group 1), lipografting combined with PRP pretreatment 7–10 days before (group 2), and lipografting on one side and lipografting combined with PRP on the contralateral side (group 3).<sup>17</sup> The methods and the data were reported in qualitative fashion, and no quantitative scar outcomes were reported. As such no conclusions could be drawn from this study.

#### Acne scars

Platelet-rich plasma has been evaluated for its potential benefits in the treatment of acne scars. Erbium fractional laser (FCL) therapy was administered to patients with facial acne scars, and topical PRP gel was applied after laser therapy.<sup>18</sup> In total, 68% and 91% of patients demonstrated a 50% or greater improvement of their scars on a quartile scale after the first and third treatment, respectively.<sup>18</sup> This study was not a split-face study, making it more difficult to assess how much of the improvement could be attributed to the PRP or the erbium FCL. Another study utilized a split-face design to examine the treatment of patients with L-PRP injections on one half and saline injections on the other half of the face after ablative carbon dioxide FCL therapy for the treatment of acne scars.<sup>19</sup> L-PRP treatment reduced the overall duration of erythema from  $10.4 \pm 2.7$  to  $8.6 \pm 2.0$  days. Furthermore, erythema was significantly less by day 4 as measured by a chromometer and the duration of edema was reduced by approximately one day on the L-PRP-treated side. The L-PRP-treated side showed significant improvements in the overall clinical appearance of acne scars compared to the control group as evaluated by independent dermatologists using a quartile grading system with a mean improvement of  $(2.7 \pm 0.7)$  for the PRP group and  $(2.3 \pm 0.5)$  for the control group.<sup>19</sup>

The comparative efficacy and safety of injected L-PRP and topical L-PRP preparations was evaluated in patients who underwent FCL treatment for acne scars.<sup>20</sup> Patients were randomized into two split-face study groups. The first group received either FCL and intradermal L-PRP or FCL and intradermal saline. The second group received either FCL and intradermal L-PRP or FCL with topical PRP. Three monthly treatments were performed with a follow-up assessment at 6 months. Both the topical and intradermal L-PRP-treated groups had shorter recovery times and demonstrated significant improvements in clinical appearance of acne scars compared to the control group that

received FCL therapy only. Optical coherence tomography measurements of acne scar depth revealed that the FCL only treatment group showed less improvement compared to the topical and intradermal L-PRP treatment. There were no significant differences between the topical and intradermal L-PRP treatment groups, but the topical L-PRP was better tolerated.<sup>20</sup>

Platelet-rich plasma appears to improve recovery after cosmetic treatments such as FCL and rhytidectomy.<sup>19–22</sup> Topical application of L-PRP to inner arms of patients who underwent FCL therapy resulted in marked reductions in the erythema and melanin index of the applied area compared to the saline control.<sup>21</sup> Transepidermal water loss was also significantly lower in the L-PRP-treated side compared to the control side. Furthermore, biopsies from the L-PRP treatment area revealed thicker collagen bundles than those from the control.<sup>21</sup>

#### Skin rejuvenation and dermal augmentation

Recent studies have used topical growth factors to improve the smoothness and decrease wrinkles in skin.<sup>23–25</sup> Because PRP contains numerous growth factors, it has been studied in skin rejuvenation applications.

One study administered three monthly injections of PRP and evaluated cosmetic improvements on the face and neck, but no control group was used.<sup>26</sup> Physicians evaluated photographs from a dermoscope, digital camera, and photographic imaging system and determined an average improvement of 24% for naso-labial folds, 28% for horizontal neck bands, 27% for skin micro-relief, 20% for snap test, 33% for skin homogeneity and texture, 22.5% for skin tonicity, and 30% for periocular wrinkles. Single injections of PRP were tested to treat infraorbital dark circles and crow's feet wrinkles.<sup>27</sup> Physician-assessed improvements in melanin content, color homogeneity, epidermal stratum corneum hydration, wrinkle volume and visibility index were assessed 3 months after treatment. Only significant improvements in color homogeneity in the infraorbital dark circles were present.<sup>27</sup> In contrast, a split-faced study on the effects of three PRP injections over the course of 12 weeks improved infraorbital wrinkles and skin tone in Asian subjects.<sup>28</sup> Patients were divided into PRP and saline injection, or platelet poor plasma and PRP injection split-face groups. Results were measured through self-assessment questionnaires combined with clinical assessment by dermatologists. Although the PRP treatments were not individually compared within each split-face treatment

group, an overall pooled comparison showed that PRP treatment significantly improved both wrinkles and skin tone in infraorbital skin.<sup>28</sup> In another study, skin biopsies of patient arms treated with intradermal and subdermal injections of PRP were associated with angiogenesis, neocollagenesis, and adipogenesis 3 weeks after the injections.<sup>29</sup> The authors described the study as utilizing PRFM, but their preparation was consistent with PRP rather than PRFM. PRP injections have been studied in the augmentation of nasolabial folds.<sup>30</sup> PRP treatment decreased the wrinkle assessment scale (WAS) score by an average of  $2.17 \pm 0.56$  immediately after treatment and  $1.13 \pm 0.72$  by 12 weeks as determined by dermatologist evaluated photographs of the patients.<sup>30</sup> No control or placebo treatments were used in this study.

Platelet-rich plasma has been evaluated in conjunction with laser-based therapies. One study evaluated the role of PRP in the augmentation of dermal collagen in study subjects that underwent three fractional erbium laser treatments.<sup>4</sup> In this study, one group received topical PRP treatment after each treatment while the other group of subjects did not.<sup>4</sup> PRP treatment combined with laser therapy increased skin elasticity as measured by an elasticity meter and decreased erythema compared to the non-PRP group. Biopsies from the PRP group increased the dermal-epidermal junction length by 67% and the number of fibroblast cells by 65.4% after treatment compared a 46.9% increase and 19.4% decrease, respectively, in the control group.<sup>4</sup>

Two case reports highlight the use of PRP in combination with autologous fat grafting.<sup>31,32</sup> Controlled studies are needed to better assess the efficacy of utilizing PRP with autologous fat grafting for facial rejuvenation and dermal augmentation.

### Striae distensae

Striae distensae are dermal scars with epidermal atrophy found in skin subjected to continuous stretching.<sup>33</sup> A combination therapy of intradermal radiofrequency and PRP was administered to patients with striae distensae once every 4 weeks.<sup>34</sup> The PRP or radiofrequency were not studied alone, and a control group was not used. After 12 weeks of treatment, physicians utilizing a quartile evaluation ranking system determined that 100% of the 19 patients showed at least mild improvement (0–25% improvement). Overall, 5.3% achieved excellent improvement, 36.8% achieved marked improvement, 31.6% achieved moderate improvement, and 26.3% achieved mild improvement.

Twelve of the nineteen patients considered the treatment to be satisfactory or very satisfactory. Ultrasound-assisted topical PRP therapy has been used to treat striae distensae after plasma fractional radiofrequency therapy.<sup>35</sup> PRP was applied with ultrasound assistance to enhance transepidermal drug penetration every 2 weeks for 8 weeks. The average width of the widest striae reduced in size from 0.75 to 0.27 mm. In total, 71.9% of the patients reported good or very good improvements in their striae distensae as well.<sup>35</sup> Furthermore, post-treatment abdominal biopsies showed increased collagen density and elastic fibers in the dermis although no quantitation was provided in the manuscript.

### Conclusion

Platelet-rich plasma is a relatively new treatment modality that may have beneficial effects for aesthetic and scar revision treatments. Most studies have evaluated the potential utility of PRP in combination therapies with other modalities such as lasers, radiofrequency, and autologous fat grafting. Notably, few studies have comparatively evaluated different subset of PRP to assess whether which subtype may be more suitable for particular indications. Clinical studies that comparatively assess different forms of PRP will help provide a better understanding of how different subsets may be utilized. Future studies should utilize control treatments, preferably split-side treatments, so that the efficacy of PRP treatments can be better defined. Moreover, the use of split-side studies will allow each subject to serve as their own control to minimize intersubject variability. Future studies should also include a detailed description of the PRP collection process, as in some of the reviewed studies it was not possible to ascertain what subtype was utilized. Although there are few large-scale clinical studies on PRP, the smaller studies support larger well-controlled studies to further assess its use.

### Acknowledgments

We are grateful to Bruce Abbott for his assistance with the systematic search protocol.

### References

- 1 Marx RE. Platelet-rich plasma (PRP): what is PRP and what is not PRP? *Implant Dent* 2001; **10**: 225–8.
- 2 Edelblute CM, Donate AL, Hargrave BY et al. Human platelet gel supernatant inactivates opportunistic wound pathogens on skin. *Platelets* 2015; **26**: 13–6.

- 3 Nicoli F, Balzani A, Lazzeri D *et al.* Severe hidradenitis suppurativa treatment using platelet-rich plasma gel and Hyalomatrix. *Int Wound J* 2015; **12**: 338–43.
- 4 Shin MK, Lee JH, Lee SJ *et al.* Platelet-rich plasma combined with fractional laser therapy for skin rejuvenation. *Dermatol Surg* 2012; **38**: 623–30.
- 5 Lubkowska A, Dolegowska B, Banfi G. Growth factor content in PRP and their applicability in medicine. *J Biol Regul Homeost Agents* 2012; **26** (2 Suppl 1): 3s–22s.
- 6 Marx RE. Platelet-rich plasma: evidence to support its use. *J Oral Maxillofac Surg* 2004; **62**: 489–96.
- 7 Foster TE, Puskas BL, Mandelbaum BR *et al.* Platelet-rich plasma: from basic science to clinical applications. *Am J Sports Med* 2009; **37**: 2259–72.
- 8 Dohan Ehrenfest DM, Rasmusson L, Albrektsson T. Classification of platelet concentrates: from pure platelet-rich plasma (P-PRP) to leucocyte- and platelet-rich fibrin (L-PRF). *Trends Biotechnol* 2009; **27**: 158–67.
- 9 Kumaran MS. Platelet-rich plasma in dermatology: boon or a bane? *Indian J Dermatol Venereol Leprol* 2014; **80**: 5–14.
- 10 Carter MJ, Fylling CP, Parnell LK. Use of platelet rich plasma gel on wound healing: a systematic review and meta-analysis. *Eplasty* 2011; **11**: e38.
- 11 Takikawa M, Nakamura S, Nakamura S *et al.* Enhanced effect of platelet-rich plasma containing a new carrier on hair growth. *Dermatol Surg* 2011; **37**: 1721–9.
- 12 Park KY, Kim HK, Kim BJ *et al.* Letter: Platelet-rich plasma for treating male pattern baldness. *Dermatol Surg* 2012; **38**: 2042–4.
- 13 Kang JS, Zheng Z, Choi MJ *et al.* The effect of CD34+ cell-containing autologous platelet-rich plasma injection on pattern hair loss: a preliminary study. *J Eur Acad Dermatol Venereol* 2014; **28**: 72–9.
- 14 Betsi EE, Germain E, Kalbermatten DF *et al.* Platelet-rich plasma injection is effective and safe for the treatment of alopecia. *Eur J Plast Surg* 2013; **36**: 407–12.
- 15 Azzena B, Mazzoleni F, Abatangelo G *et al.* Autologous platelet-rich plasma as an adipocyte in vivo delivery system: case report. *Aesthetic Plast Surg* 2008; **32**: 155–8; discussion 9–61.
- 16 Cervelli V, Nicoli F, Spallone D *et al.* Treatment of traumatic scars using fat grafts mixed with platelet-rich plasma, and resurfacing of skin with the 1540 nm non-ablative laser. *Clin Exp Dermatol* 2012; **37**: 55–61.
- 17 Majani U, Majani A. Correction of scars by autologous fat graft and platelet rich plasma (PRP). *Acta Med Mediterr* 2012; **28**: 99–100.
- 18 Zhu JT, Xuan M, Zhang YN *et al.* The efficacy of autologous platelet-rich plasma combined with erbium fractional laser therapy for facial acne scars or acne. *Mol Med Rep* 2013; **8**: 233–7.
- 19 Lee JW, Kim BJ, Kim MN *et al.* The efficacy of autologous platelet rich plasma combined with ablative carbon dioxide fractional resurfacing for acne scars: a simultaneous split-face trial. *Dermatol Surg* 2011; **37**: 931–8.
- 20 Gawdat HI, Hegazy RA, Fawzy MM *et al.* Autologous platelet rich plasma: topical versus intradermal after fractional ablative carbon dioxide laser treatment of atrophic acne scars. *Dermatol Surg* 2014; **40**: 152–61.
- 21 Na JI, Choi JW, Choi HR *et al.* Rapid healing and reduced erythema after ablative fractional carbon dioxide laser resurfacing combined with the application of autologous platelet-rich plasma. *Dermatol Surg* 2011; **37**: 463–8.
- 22 Powell DM, Chang E, Farrow EH. Recovery from deep-plane rhytidectomy following unilateral wound treatment with autologous platelet gel: a pilot study. *Arch Facial Plast Surg* 2001; **3**: 245–50.
- 23 Fitzpatrick RE, Rostan EF. Reversal of photodamage with topical growth factors: a pilot study. *J Cosmet Laser Ther* 2003; **5**: 25–34.
- 24 Atkin DH, Trookman NS, Rizer RL *et al.* Combination of physiologically balanced growth factors with antioxidants for reversal of facial photodamage. *J Cosmet Laser Ther* 2010; **12**: 14–20.
- 25 Mehta RC, Smith SR, Grove GL *et al.* Reduction in facial photodamage by a topical growth factor product. *J Drugs Dermatol* 2008; **7**: 864–71.
- 26 Redaelli A, Romano D, Marciano A. Face and neck revitalization with platelet-rich plasma (PRP): clinical outcome in a series of 23 consecutively treated patients. *J Drugs Dermatol* 2010; **9**: 466–72.
- 27 Mehryan P, Zartab H, Rajabi A *et al.* Assessment of efficacy of platelet-rich plasma (PRP) on infraorbital dark circles and crow's feet wrinkles. *J Cosmet Dermatol* 2014; **13**: 72–8.
- 28 Kang BK, Shin MK, Lee JH *et al.* Effects of platelet-rich plasma on wrinkles and skin tone in Asian lower eyelid skin: preliminary results from a prospective, randomised, split-face trial. *Eur J Dermatol* 2014; **24**: 100–1.
- 29 Sclafani AP, McCormick SA. Induction of dermal collagenesis, angiogenesis, and adipogenesis in human skin by injection of platelet-rich fibrin matrix. *Arch Facial Plast Surg* 2012; **14**: 132–6.
- 30 Sclafani AP. Platelet-rich fibrin matrix for improvement of deep nasolabial folds. *J Cosmet Dermatol* 2010; **9**: 66–71.
- 31 Park KY, Kim IS, Kim BJ *et al.* Letter: autologous fat grafting and platelet-rich plasma for treatment of facial contour defects. *Dermatol Surg* 2012; **38**: 1572–4.
- 32 Willemsen JC, Lindenblatt N, Stevens HP. Results and long-term patient satisfaction after gluteal augmentation with platelet-rich plasma-enriched autologous fat. *Eur J Plast Surg* 2013; **36**: 777–82.
- 33 Al-Himdani S, Ud-Din S, Gilmore S *et al.* Striae distensae: a comprehensive review and evidence-based evaluation of prophylaxis and treatment. *Br J Dermatol* 2014; **170**: 527–47.



- 34 Kim IS, Park KY, Kim BJ *et al.* Efficacy of intradermal radiofrequency combined with autologous platelet-rich plasma in striae distensae: a pilot study. *Int J Dermatol* 2012; **51**: 1253–8.
- 35 Suh DH, Lee SJ, Lee JH *et al.* Treatment of striae distensae combined enhanced penetration platelet-rich plasma and ultrasound after plasma fractional radiofrequency. *J Cosmet Laser Ther* 2012; **14**: 272–6.

Copyright of Journal of Cosmetic Dermatology is the property of Wiley-Blackwell and its content may not be copied or emailed to multiple sites or posted to a listserv without the copyright holder's express written permission. However, users may print, download, or email articles for individual use.