

# Platelet rich plasma versus laser therapy in lateral epicondylitis of elbow

Gyaneshwar Tonk, Anish Kumar, Amit Gupta

## ABSTRACT

**Background:** Platelet rich plasma (PRP) extract has shown to be a general stimulation for repair and currently used widely in various sports injury. A prospective observational study was done to assess the efficacy of autologous PRP injection in lateral epicondylitis of elbow, and compare the result with low level laser therapy.

**Materials and Methods:** The trial was conducted at a tertiary care center for a period of 2 years. Eighty-one patients with chronic lateral epicondylitis were divided into two groups. PRP group ( $n = 39$ ) and laser therapy group ( $n = 42$ ). The primary analysis included Nirschl pain score, local tenderness, pain on wrist extension, grip strength, elbow swelling were clinically assessed at different interval of followup (minimum followup: 52 weeks) and; clinical and functional outcome evaluated at final followup. The statistical analysis were done.

**Results:** The mean Nirschl pain score decreased significantly from baseline in PRP when compared with low level laser therapy ( $P \leq 0.05$ ).

**Conclusions:** Treatment of patients with chronic lateral epicondylitis with PRP extract reduced pain and significantly increased function, exceeding the effect of low level laser therapy on long term followup. Low-level laser therapy is better in the short term period, but on long term followup injection PRP therapy is better than laser therapy in lateral epicondylitis.

**Key words:** Lateral epicondylitis, low level laser therapy, Nirschl pain score, platelet rich plasma injection

**MeSH terms:** Elbow, tendinopathy, laser therapy, platelets, plasma

## INTRODUCTION

Lateral epicondylitis result from cumulative micro trauma due to repetitive wrist extension and alternating forearm supination and pronation.<sup>1,2</sup> Angiofibroblastic degeneration of the origin of the extensor carpi radialis brevis (ECRB) is believed by most investigators to be the most common cause.<sup>3,4</sup>

Extra corporeal shock wave therapy,<sup>5</sup> laser therapy,<sup>6,7</sup> autologous blood injection<sup>6</sup> and platelet rich plasma (PRP) have been used to treat lateral epicondylitis.

We report a long term followup study on the efficacy of

autologous PRP when compared to low level laser therapy in lateral epicondylitis.

## MATERIALS AND METHODS

The proposed study was conducted at a tertiary care center. Patients between 20 and 70 years of age who presented after 7 days of onset of pain and one of the following clinical positive tests were included in the study: Tenderness elicited just distal and anterior to the lateral epicondyle, pain with resisted wrist extension with an elbow in full extension, Coffee cup test - picking up a full cup of coffee/water associated with localized pain at lateral epicondylar region, chair test - picking up chair with extended elbow, Thomson test-flex the patient shoulder to 60° with the elbow extended forearm pronated and wrist extended 30°, apply pressure to dorsum of second and third metacarpal in the direction of flexion and ulnar deviation and Cozens test - flex elbow and extended wrist against resistance.

Patients with rheumatoid arthritis of elbow, cervical radiculitis, infective pathology, neoplastic lesion, dermatomyositis, previous trauma around elbow, patients previously treated surgically for lateral epicondylitis, patients who had received steroid injection within 3 months, patients with elbow instability (assessed by varus valgus instability test) were excluded from this study.

Department of Orthopaedics, LLRM Medical College, Meerut, Uttar Pradesh, India

**Address for correspondence:** Dr. Gyaneshwar Tonk, Department of Orthopaedics, LLRM Medical College, Meerut, Uttar Pradesh, India. E-mail: gyaneshwartonk@gmail.com

Access this article online	
Quick Response Code:	Website: www.ijoonline.com
	DOI: 10.4103/0019-5413.136260

The treatment options were discussed with patients and close relatives. An informed consent was taken for nonrandomized prospective study. The study was approved by institutional ethical committee (No S-1/2013/3847).

All cases were treated initially with brace, nonsteroidal analgesics and cold therapy (10-15 min of ice, 4-5 times a day) for 1 week. Patients who did not respond were included in this study. Patients who gave consent for local injection were treated by platelet rich extract injection (Group 1 PRP group) while others were treated by intermittent laser therapy for 10 days (Group 2 laser group) while. Result of both groups was evaluated and compared according to four point pain scale and Nirschl staging system of pain. These pain scoring systems are simple to use and have been used in previous studies.<sup>8</sup> Complications in both the modalities was noted.

### Technique

1. PRP injection - 55 ml of blood was taken from the patients. Centrifuge vial was preloaded with 3 mg of anticoagulant citrate dextrose-A. The blood was then prepared by gravity separation method instructions to yield 4 ml of PRP at the junction of plasma and red blood cell concentrate. This blood was centrifuged at 700 rpm (120 G) for 20 min. The plasma was again centrifuged at 1750 rpm (800 G) for 15 min to yield 3 ml of PRP at the bottom and one milliliter of this PRP was sent to the laboratory for analysis of platelet concentration (the total number of platelets per milliliter in the PRP)<sup>9</sup> which represented a mean increase of 509% compared with whole blood values in the active patient group. Initially, we gave a local field block in the form of 1 ml of 2% xylocaine. We used 3 ml of PRP without any activator. We used it with a 22 gauge syringe at the site of maximum tenderness (or lateral epicondyle) and in the vicinity (around the tendon of ECRB). This technique involved a single skin portal and then five penetrations of the tendon. The elbow was kept in sling for comfort. After 24 h, patients were taught a standardized stretching protocol to follow for 2 weeks. Forearm strengthening program was initiated after this stretching. At 3 weeks after the procedure, patients were allowed to proceed with normal sporting or recreational activities as tolerated
2. Low level laser therapy - we used 904 nm wavelength lasers. The probe of laser unit was directed to the point of tenderness in the soft tissue at a right angle to the surface of the skin. Duration of each session was for 5 min. In addition, for patient with bilateral symptoms one elbow was treated at a time to avoid inconvenience to the patient due to postinjection transient pain. Forearm strengthening program was initiated as in PRP injection technique [Figure 1].

Patients were asked to rate their pain according to - Nirschl pain score [Table 1].<sup>3</sup>

### Evaluation

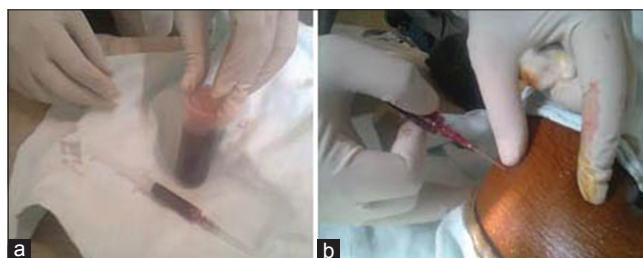Patients were reassessed at 7<sup>th</sup> day, 15<sup>th</sup> day, 21<sup>st</sup> day, 2 month, and 3 month, 5 month, 6 month and 12 months. For statistical analysis, repeated measure analysis of variance technique with multiple comparisons by using Bonferroni technique, Student *t*-test, Chi-square test, and Fisher exact test have been used.

### RESULTS

The study comprised a total of 81 patients (30 males and 51 females) of lateral epicondylitis treated between January 2010 and September 2011. The mean patient age was 41.15 years in PRP group (range 24-73 years) 39.76 years for laser group (range 20-65 years). It is statistically not significant in both groups ( $P = 0.081$ ). A total of 81 patients were included for study. Of these four patients (two in PRP and two in the laser group) relapsed. Three patients failed to respond treatment (one PRP and two laser group). There was no complication in any patient.

Patient in PRP group, 20 (51.28%) were male and 19 (48.71%) were female whereas in the laser group 10 (23.80%) were male and 32 (76.20%) were female.

There were 28 (71.79%) cases of subacute type and 11 (28.21%) were chronic cases in PRP group, whereas



**Figure 1:** Preinjection photograph of blood sample technique (a) platelet rich plasma separated from vial (b) platelet rich plasma injection technique

**Table 1: Nirschl staging**

Phase	Clinical features
Phase 1	Mild pain with exercise, resolve within 24 h
Phase 2	Pain after exercise, exceeding 48 h
Phase 3	Pain with exercise, does not alter activity
Phase 4	Pain with exercise, alter activity
Phase 5	Pain with heavy activity of daily living
Phase 6	Pain with light activity of daily living, intermittent pain at rest
Phase 7	Constant pain at rest, disrupt sleep

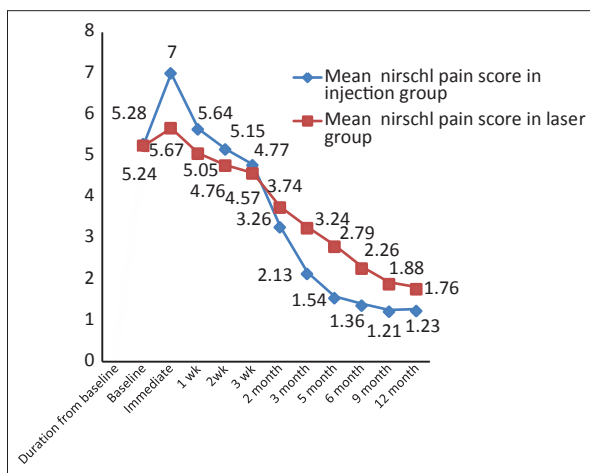
in the laser group there were 22 (52.39%) subacute cases and 20 (47.61%) chronic cases [Table 2]. For within group comparison in PRP group, the results were statistically significant ( $P \leq 0.05$ ). The mean Nirschl pain score decreases from baseline continuously up to 9 month significantly except immediately, at 1 week and at 12 month [Figure 2].

We had seen that within group comparison for laser therapy results are statistically significant. The Nirschl pain score decreases continuously from baseline up to 12 month except immediately. When both treatment methods were compared then it was observed that these two methods differ significantly from immediate to 12 month except 3 week and 2 month. It was evident that until 2 week pain score was higher significantly in injection method (Group 1)

**Table 2: Baseline characteristics between PRP and laser group**

Character	Mean±SD		P value
	PRP group	Laser group	
Age	41.15±12.63	39.76±9.31	0.081
Sex			
Male	20	10	0.011
Female	19	32	
Mode of onset			
Subacute	28	22	0.072
Chronic	11	20	
Nirschl pain	5.28±0.83	5.24±0.76	0.669
Mean duration of pain	37.30	46.37	0.086
Elbow disability			
Yes	21	24	0.762
No	19	19	
Grip strength			
Yes	19	20	0.928
No	21	23	
Elbow swelling			
Yes	3	2	0.586
No	37	41	

PRP=Platelet rich plasma, SD=Standard deviation



**Figure 2:** A group graph showing Nirschl pain score followup in PRP and laser group

when compared with laser (Group 2). From 3 months the pain score was lower significantly in injection group when compared with laser group and was statistically significant. It can be concluded that low level laser therapy is better in the short term period, but upto 1 year followup, injection PRP therapy is better than laser therapy.

We had seen that up to 2 months there is no statistical association of treatment method with point of tenderness and pain on wrist extension ( $P > 0.05$ ) in both groups. However, it was noted that as the duration increase number of patient having point tenderness and pain on wrist extension in injection group decreases as compared to laser group. However, statistically significant up to 6 months only ( $P < 0.05$ ). There was no statistically significant association of treatment methods with grip strength and elbow swelling in both of the group.

## DISCUSSION

Lateral elbow pain is a frequent cause of disability in patients and most commonly it is diagnosed as lateral epicondylitis or tennis elbow. The fact that there is more than one type of treatment options available in treatment suggests that no single procedure is effective in all patients. The most commonly recommended treatment is physical therapy and corticosteroid injections. Corticosteroids have a high frequency of relapse and recurrence, probably because intratendinous injection may lead to permanent adverse changes within the structure of the tendon and because patients tend to overuse the arm after injection as a result of direct pain relief.<sup>10</sup> Extracorporeal shock wave therapy also has recently gained popularity. A recent randomized double-blind study, however, showed that this treatment is no better than placebo.<sup>5</sup> Edwards and Calandruccio using whole blood noted a 79% success rate when treating lateral epicondylitis. The followup time, however, was short (9.5 months), and 32% of the time, multiple injections were required.<sup>8</sup> The concentrated growth factors within PRP work in concert to initiate a healing response within a damaged tendon. This hypothesis is supported by *in vitro* data from Klein *et al.* They have reported that transforming growth factor beta significantly increases type I collagen production in tendon sheath fibroblasts.<sup>11</sup> Mishra and Pavelko<sup>12</sup> injected PRP for chronic elbow tendinosis and at a final followup of 12-38 months, patients reported 93% reduction in pain compared with the preinjection status.

Bjordal, *et al.*<sup>6</sup> performed a review of randomized placebo-controlled trials with laser therapy for tendinopathy the effect of laser therapy for patients with subacute and chronic tendinopathy. Laser therapy can reduce pain in subacute and chronic tendinopathy if a valid treatment procedure and location-specific dose is used.

Vasseljen *et al.*<sup>7</sup> conducted a study using a 904 nm wavelength, GaAs laser with 12 diodes covering 20 cm<sup>2</sup>. Low level laser therapy was provided at a distance of 8 mm from the skin for 10 min for a dose of 3.5 J/cm<sup>2</sup>. After dividing patients into acute and chronic cases, patients were randomized to active laser or placebo laser. Sessions occurred 3 times/week for a total of eight treatments. Low level laser therapy was shown to have an effect over placebo; however, as a sole treatment for lateral epicondylitis, it is of limited value.

The foregoing hypothesis supports the following one of how PRP may regenerate tendon or muscle function. PRP is applied in an unactivated form that becomes activated by the collagen within connective tissue. The PRP then releases its growth factors and cytokines. These bioactive proteins in turn stimulate local stem cells and enhance extra cellular matrix gene expression.<sup>13</sup> Recruitment of reparative cells from the local circulation or bone marrow then occurs. Simultaneously, PRP inhibits excess inflammation, apoptosis, and metalloproteinase activity. These interactive pathways may result in the restoration of tendon or muscle tissue, which can withstand loading with work or sports activity, thereby diminishing pain. PRP may also modulate the microvascular environment or alter efferent or afferent neural receptors. Much more investigation is required to verify the mechanism (s) of action of PRP.<sup>14</sup>

In this study in Group 1 mean Nirschl pain score decreased statistically from baseline up to 9 month except immediate and 1 week ( $P < 0.05$ ). In laser group (Group 2) Nirschl pain score decreases continuously from baseline up to 12 month except immediately. When both treatment methods were compared then it was observed that these two methods differ significantly from immediate to 12 month except 3 week and 2 month. It was evident that until 2 week pain score was higher significantly in injection method (Group 1) as compared with laser (Group 2). After 2 week pain score was lower in injection group as compared to laser group and was statistically significantly decreasing trend was observed with increasing time period in injection group.

The limitations of this study include lack of a randomized control group and the small number of patients. We could not measure concentration of different growth factors present in the PRP.

To conclude the low level laser therapy is better in short term period but in long term followup (1 year), PRP therapy is better than laser therapy.

## REFERENCES

1. Cyriax JH. The pathology and treatment of tennis elbow. *J Bone Joint Surg* 1936;18A: 921-40.
2. Coonrad RW, Hooper WR. Tennis elbow: Its course, natural history, conservative and surgical management. *J Bone Joint Surg Am* 1973;55:1177-82.
3. Nirschl RP. The etiology and treatment of tennis elbow. *J Sports Med* 1974;2:308-23.
4. Kraushaar BS, Nirschl RP. Tendinosis of the elbow (tennis elbow). Clinical features and findings of histological, immunohistochemical, and electron microscopy studies. *J Bone Joint Surg Am* 1999;81:259-78.
5. Haake M, König IR, Decker T, Riedel C, Buch M, Müller HH, *et al.* Extra corporeal shock wave therapy in the treatment of lateral epicondylitis: A randomized multicenter trial. *J Bone Joint Surg Am* 2002;84-A: 1982-91.
6. Bjordal JM, Couppe C, Ljunggren AE. Low level laser therapy for tendinopathy: evidence of a dose response. *Phys Ther Rev* 2001;6:91-9.
7. Vasseljen O Jr, Høeg N, Kjeldstad B, Johnsson A, Larsen S. Low level laser versus placebo in the treatment of tennis elbow. *Scand J Rehabil Med* 1992;24:37-42.
8. Edwards SG, Calandruccio JH. Autologous blood injections for refractory lateral epicondylitis. *J Hand Surg Am* 2003;28:272-8.
9. Landesberg R, Roy M, Glickman RS. Quantification of growth factor levels using a simplified method of platelet-rich plasma gel preparation. *J Oral Maxillofac Surg* 2000;58:297-300.
10. Smidt N, van der Windt DA, Assendelft WJ, Devillé WL, Korthals-de Bos IB, Bouter LM. Corticosteroid injections, physiotherapy, or a wait-and-see policy for lateral epicondylitis: A randomised controlled trial. *Lancet* 2002;359:657-62.
11. Klein MB, Yalamanchi N, Pham H, Longaker MT, Chang J. Flexor tendon healing *in vitro*: Effects of TGF-beta on tendon cell collagen production. *J Hand Surg Am* 2002;27:615-20.
12. Mishra A, Pavelko T. Treatment of chronic elbow tendinosis with buffered platelet-rich plasma. *Am J Sports Med* 2006;34:1774-8.
13. Molloy T, Wang Y, Murrell G. The roles of growth factors in tendon and ligament healing. *Sports Med* 2003;33:381-94.
14. Mishra A, Woodall J Jr, Vieira A. Treatment of tendon and muscle using platelet-rich plasma. *Clin Sports Med* 2009;28:113-25.

**How to cite this article:** Tonk G, Kumar A, Gupta A. Platelet rich plasma versus laser therapy in lateral epicondylitis of elbow. *Indian J Orthop* 2014;48:390-3.

**Source of Support:** Nil, **Conflict of Interest:** None.

Copyright of Indian Journal of Orthopaedics is the property of Medknow Publications & Media Pvt. Ltd. and its content may not be copied or emailed to multiple sites or posted to a listserv without the copyright holder's express written permission. However, users may print, download, or email articles for individual use.